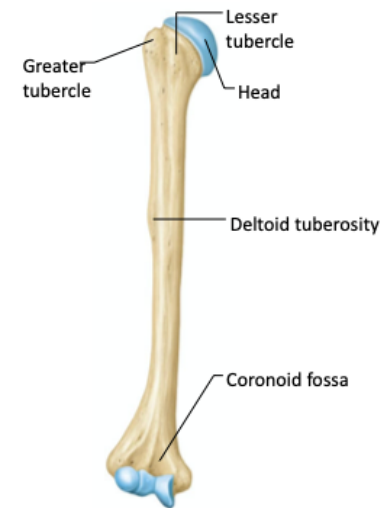
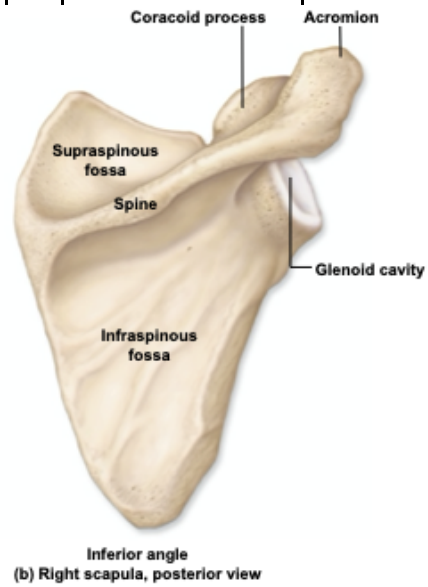
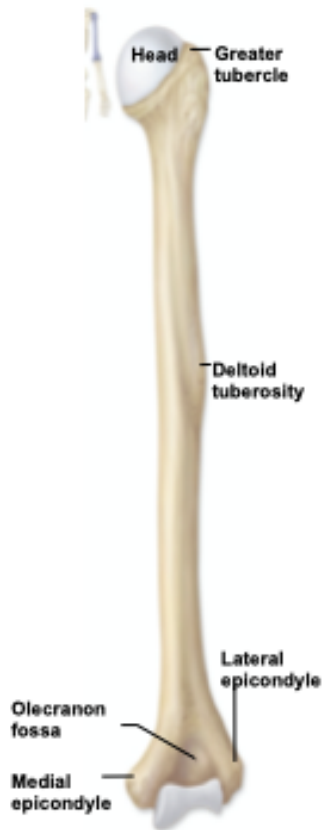

	Joint	Bone Articulations	Structural Classification	Motion	Description of movement	Muscle(s) responsible	Location of muscles	
1	Neck: Atlanto-occipital	Atlas: superior articular facets Occipital bone: occipital cond	Condylar	A1	Flexion	Sternocleidomastoid		
				A2	Extension			
				A3	Hyperextension			
	Neck: Atlantoaxial			B1				
	Spine: intervertebral				C1		Erector spinae group	Vertebral
					C2			
C3								

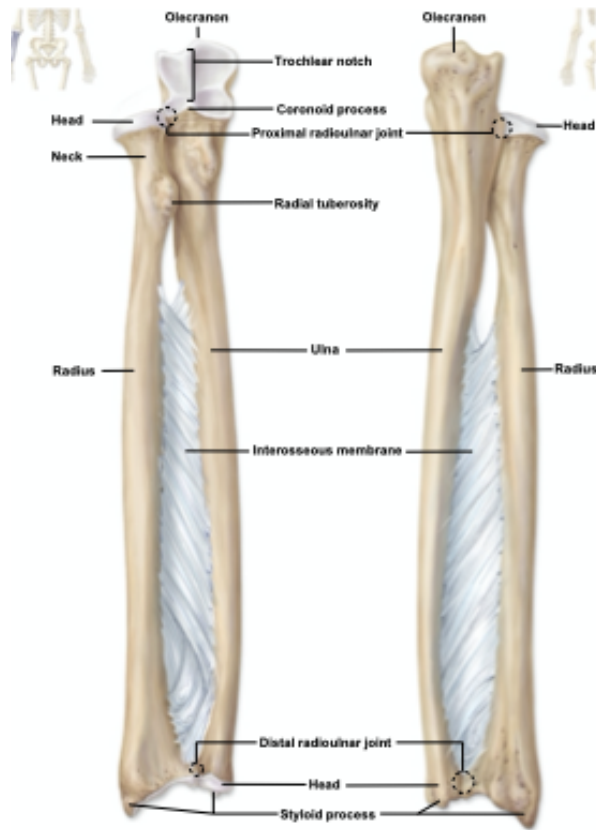
	Joint	Bone Articulations	Structural Classification	Motion	Description of movement	Muscle(s) responsible	Location of muscles
2	Glenohumeral			1			
				2			
				3			
				4			
				5			
				6			
				7			



	Joint	Bone Articulations	Structural Classification	Motion	Description of movement	Muscle(s) responsible	Location of muscles
3	Elbow			A1			
				A2			
	Radioulnar			B1			
				B2			



(b) Right humerus, posterior view

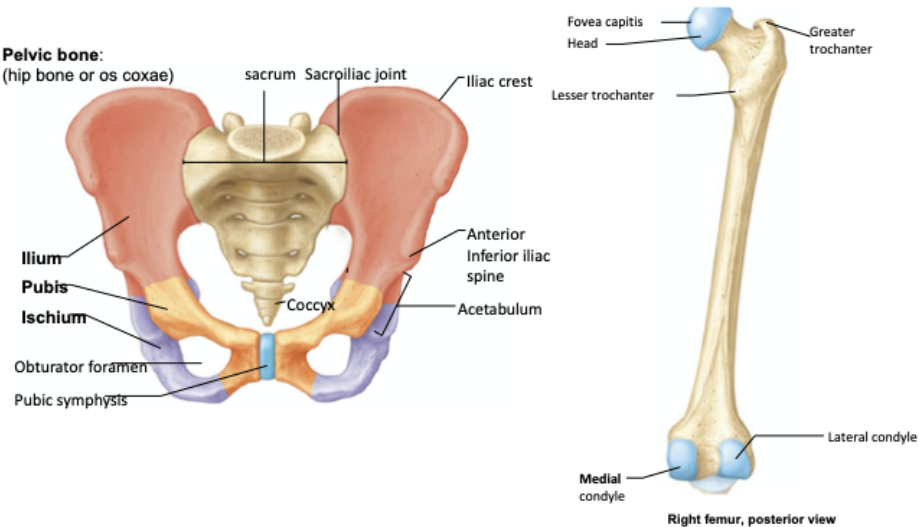


(a) Right radius and ulna, anterior view

(b) Right radius and ulna, posterior view

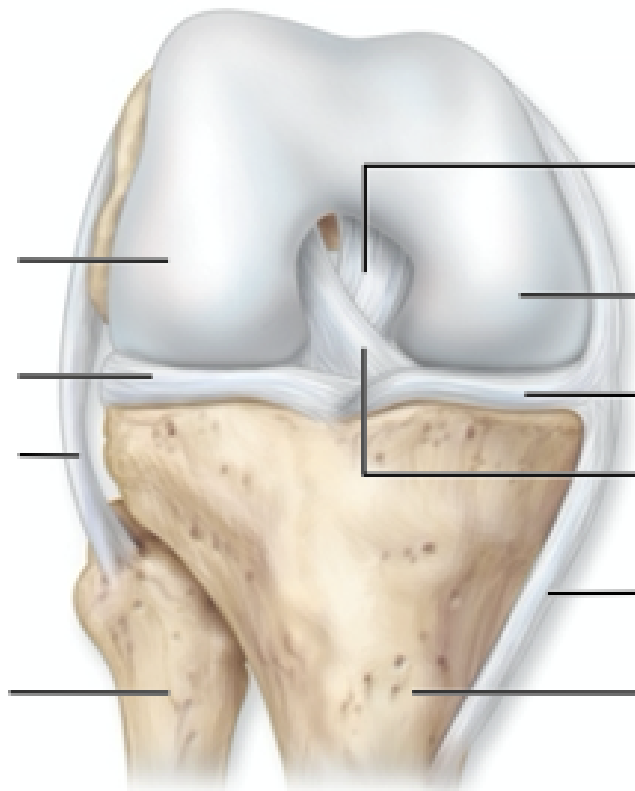
	Joint	Bone Articulations	Structural Classification	Motion	Description of movement	Muscle(s) responsible	Location of muscles
4	Hip (coaxal)			1			
				2			
				4			
				5		Adductor group (longus, brevis & magnus)	Medial femoral
				6		Tensor fasciae latae	Lateral coxal
				7			
				8			

**Pelvic bone:**  
(hip bone or os coxae)

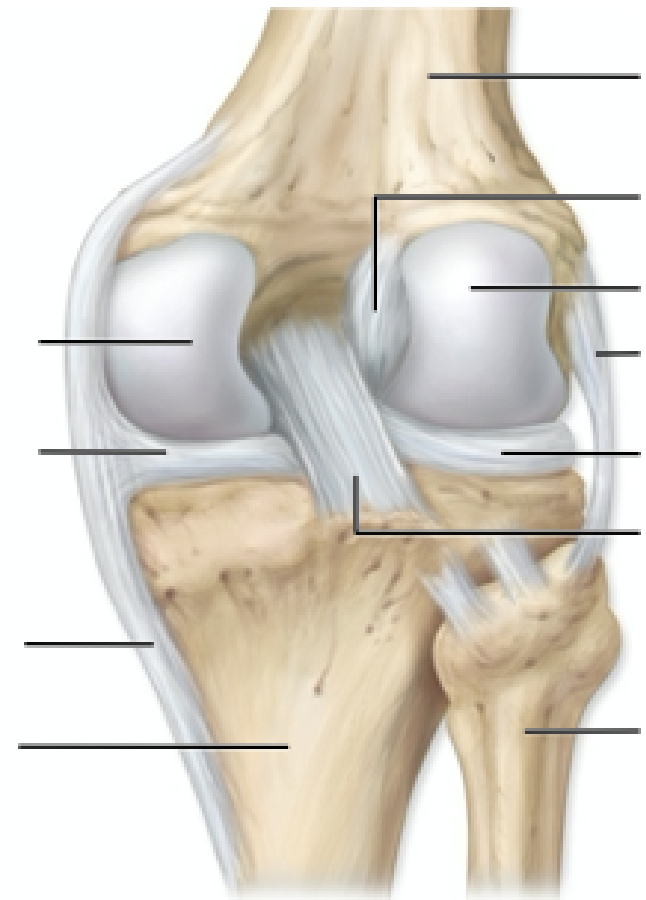


	Joint	Bone Articulations	Structural Classification	Motion	Description of movement	Muscle(s) responsible	Location of muscles
5	Knee: Tibiofemoral joint Patellofemoral joint			1			
				2			

- Femur
- Tibia
- Fibula
- Lateral meniscus
- Medial meniscus
- Posterior cruciate ligament
- Anterior cruciate ligament
- Tibial (medial) collateral
- Fibular (lateral) collateral



(c) Right knee, anterior deep view



(d) Right knee, posterior deep view

	Joint	Bone Articulations	Structural Classification	Motion	Description of movement	Muscle(s) responsible	Location of muscles
6	Ankle (Talocrural)			A1			
				A2			
	Metacarpophalangeal (knuckle)			B1			
				B2			
				B3			
				B4			
	Carpometacarpal of digit I			C1			
				C2			
					Flexion		
					Extension		
					Abduction		
		Adduction					